



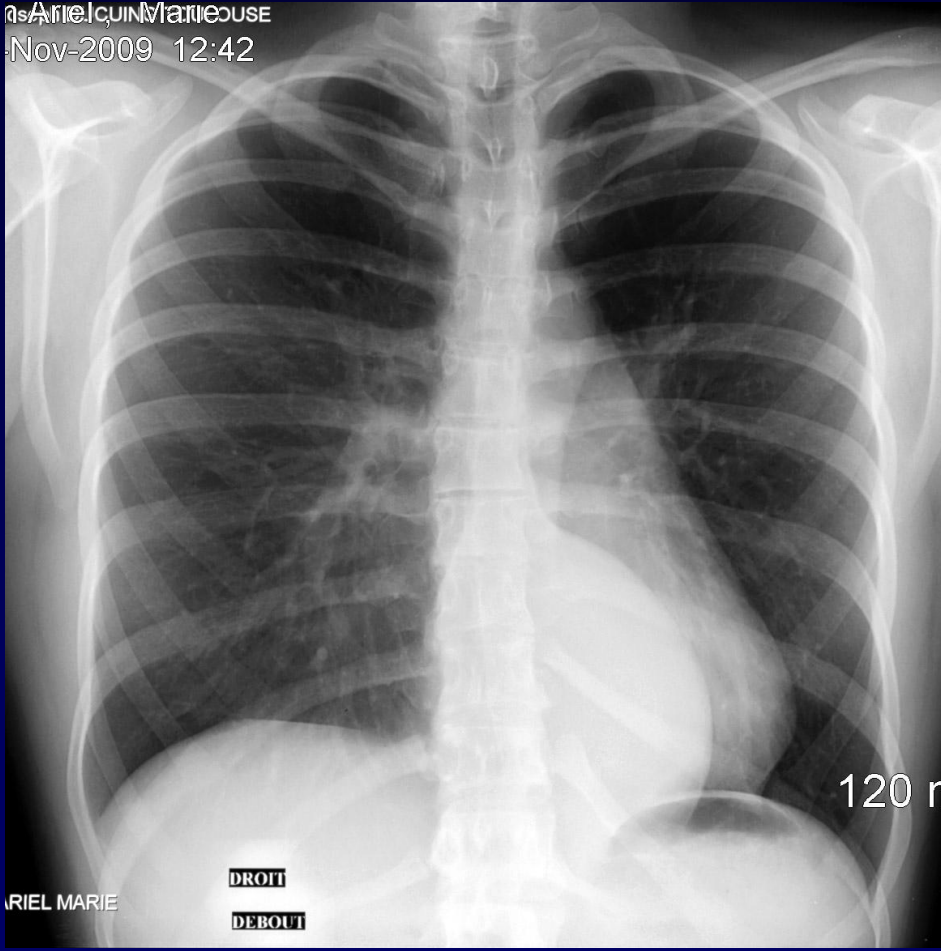
J . LEGRUSSE -J . GIRON – P . FAJADET

F, 20 ans

ASYMPTOMATIQUE, RT NATURALISATION



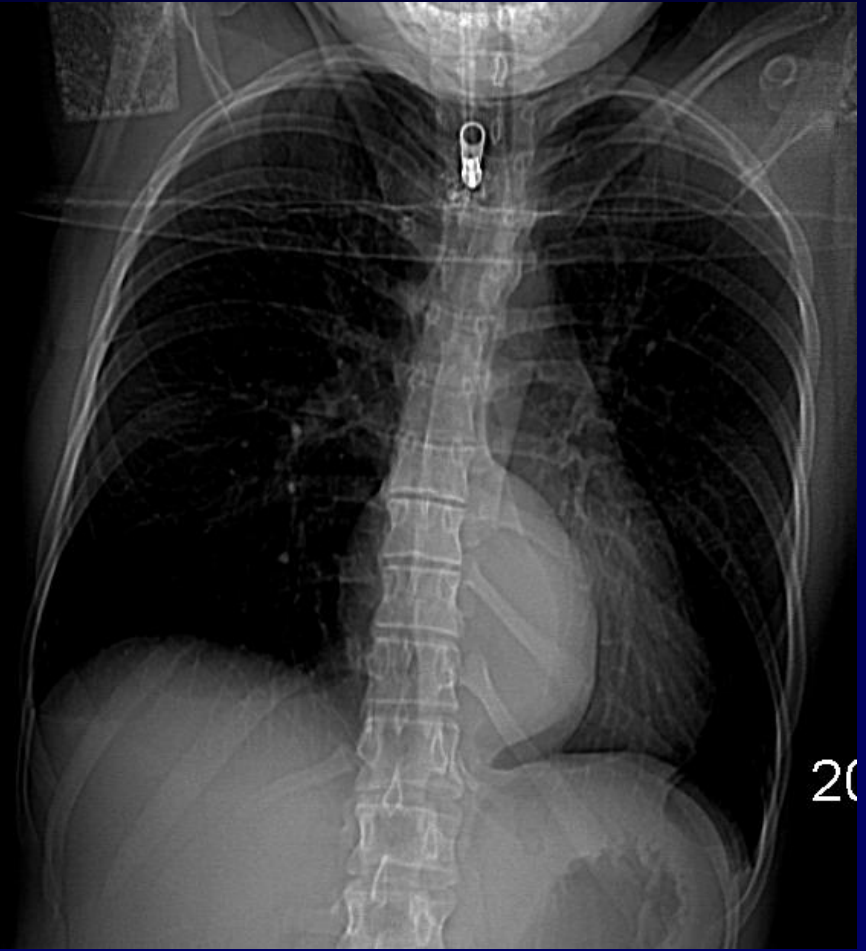
as Ariel Cun Marieuse
Nov-2009 12:42



RIEL MARIE

DROIT
DEBOUT

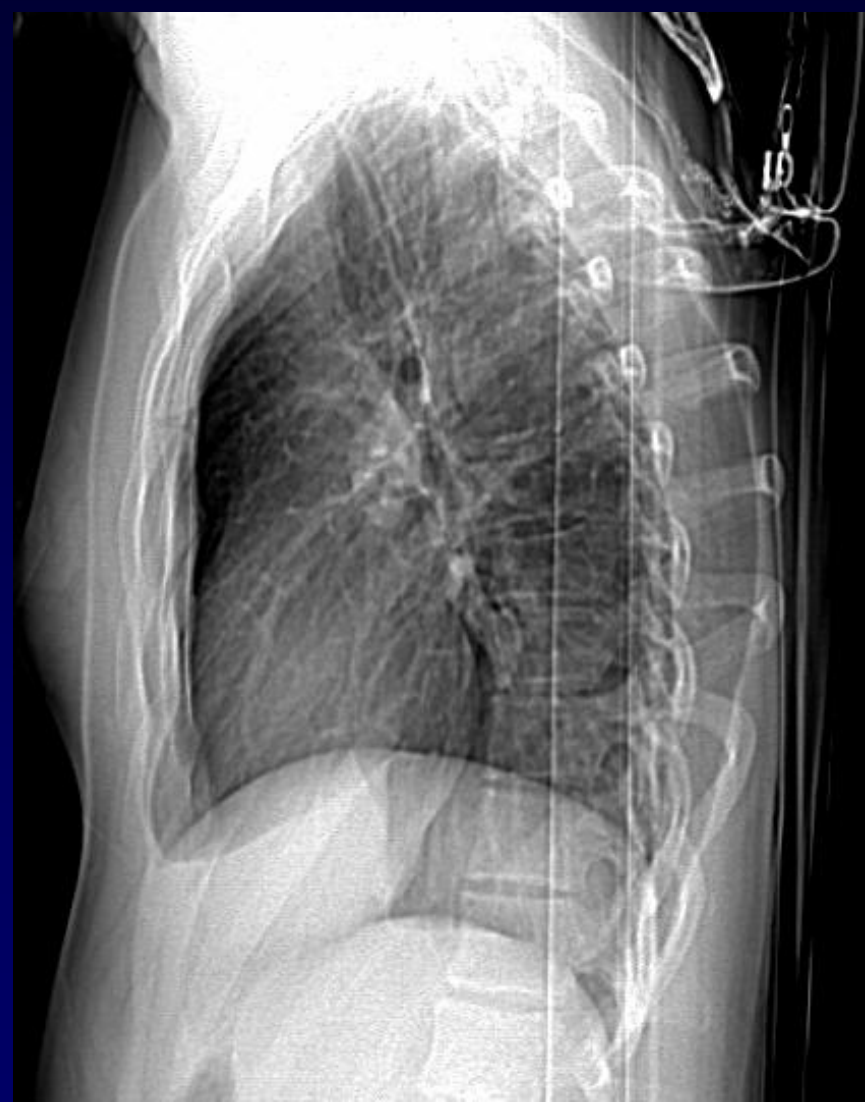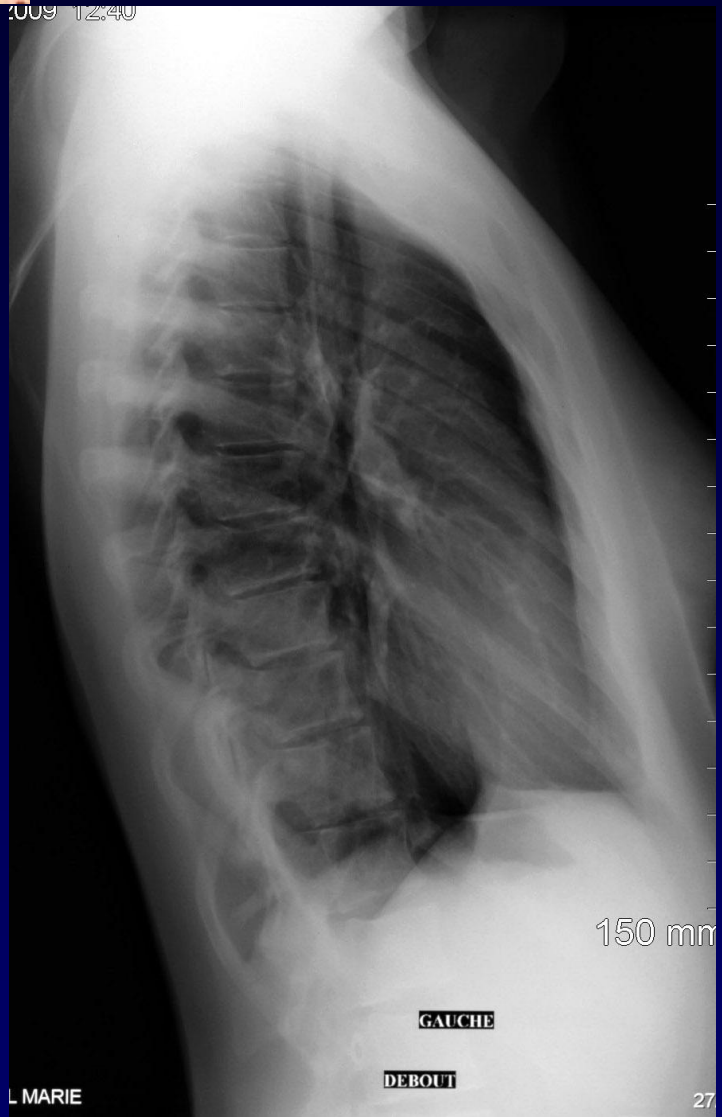
120 n

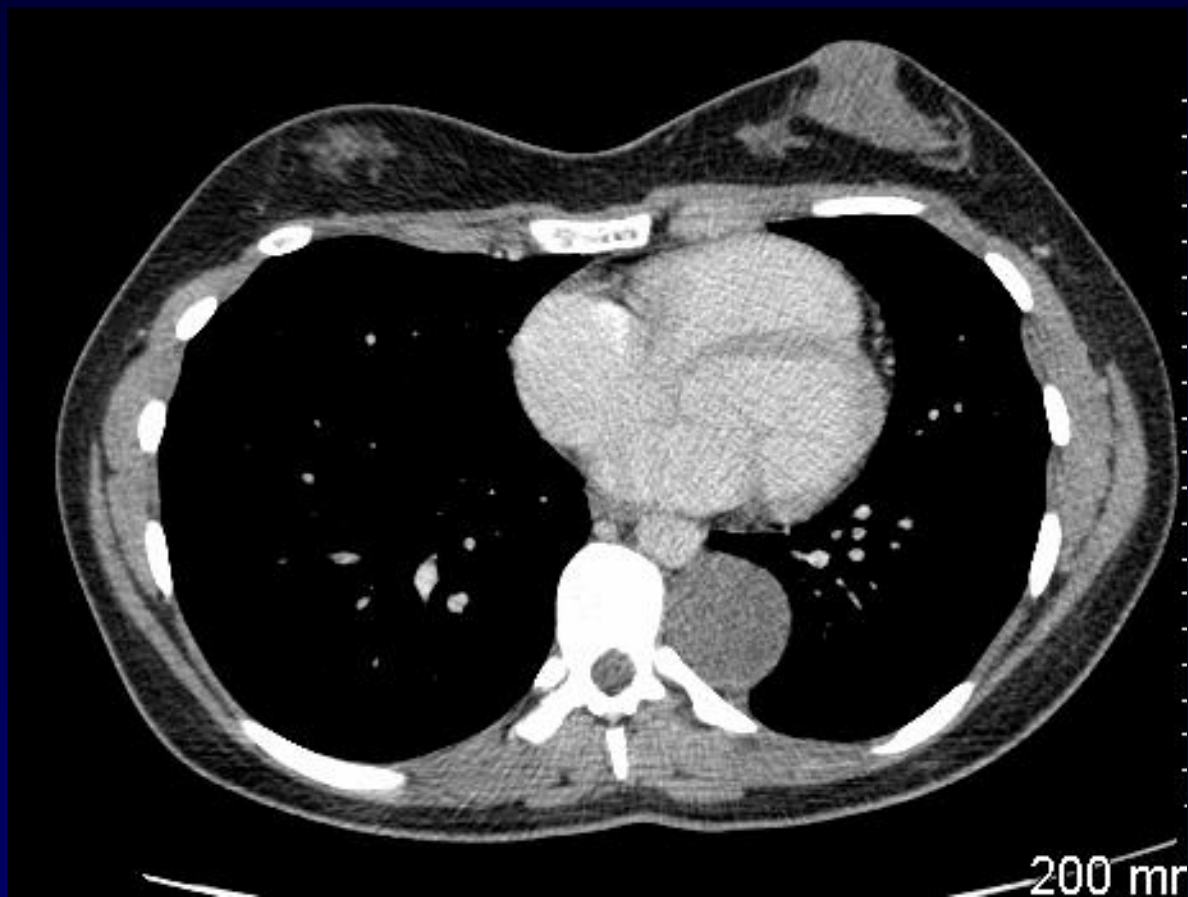


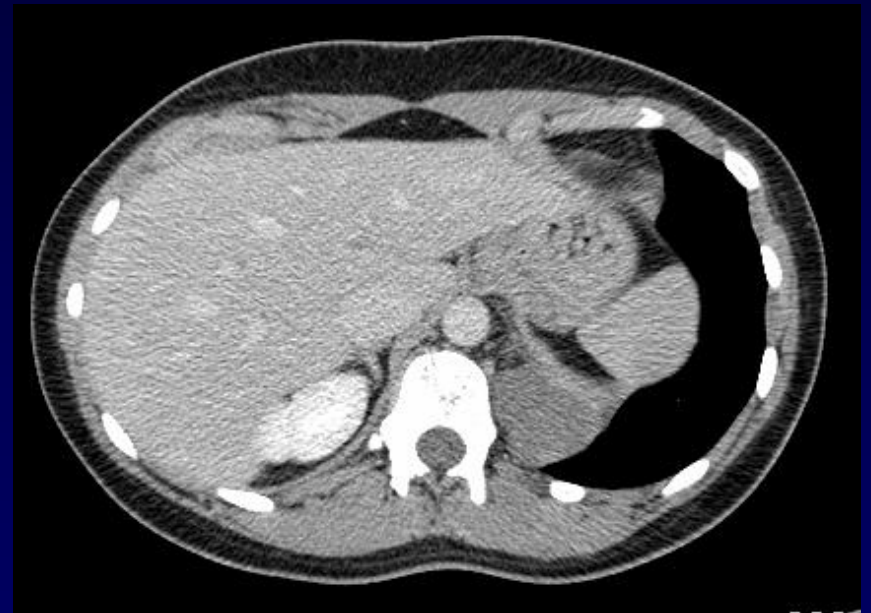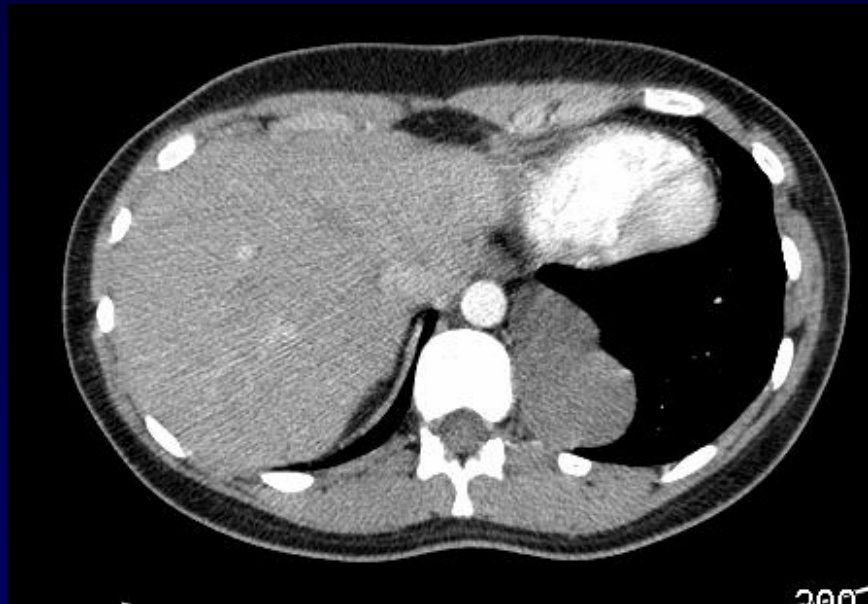20

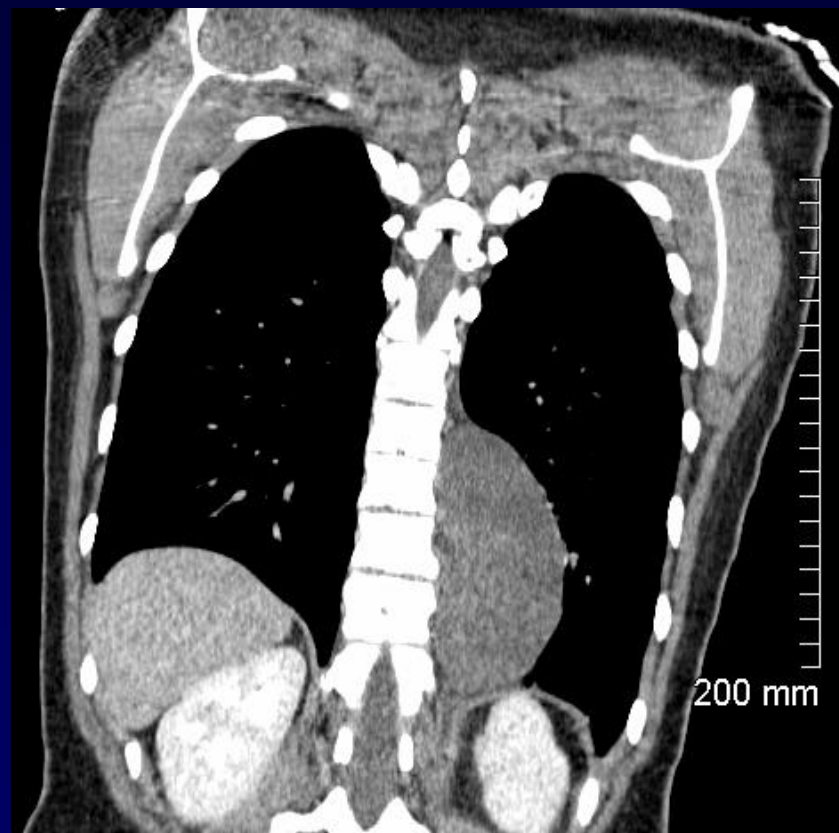
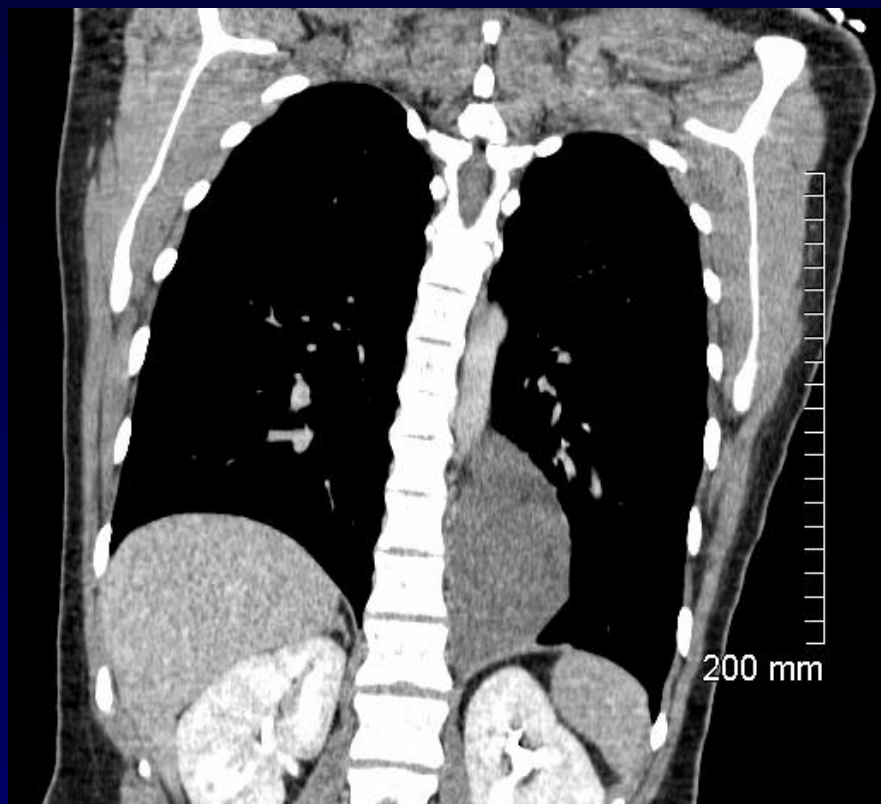
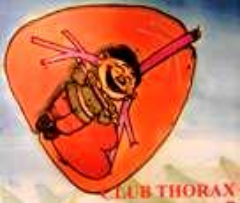

2009 12:40



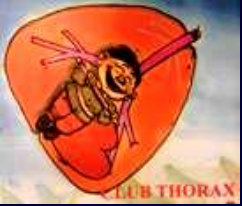







Diagnostic ?



Diagnostic

Clinique : asymptomatique

TOPO: MEDIASTIN POST

DENSITE: 30 UH (LIQUIDE IMPUR ?)

**GAMUT : KYTE BRONCHOGENIQUE ++
 KYTE NEURO-ENTERIQUE
 LYMPHANGIOME KYSTIQUE
 KYTE PLEURO- PERICARDIQUE - -**